

## A Review on Candidiasis: Types and Medications

V. Sravanthi\*<sup>1</sup>, Mayure vijay kumar<sup>1</sup>, Donthineni Kalyan<sup>2</sup>, C.P.Meher<sup>1</sup>, G.J.Finny<sup>1</sup>

<sup>1</sup>Department of pharmaceutical chemistry, Maheshwara College of Pharmacy

<sup>2</sup>Department of Pharmaceutical Analysis, Saraswathi College of Pharmaceutical Sciences.

Hyderabad, Andhra Pradesh, India

\*v.sravanthi27@gmail.com



### ABSTRACT

Candida albicans are the most effective organism that makes quite an yeast infection to form a inflammation in the different parts of the body like oral, vaginal, hepatic, renal etc..., During the infection of Candidiasis there are less chances of human death can occur, but in patient with damaged immune systems there is a chance of death, but to the Candidiasis flow to the blood streams and kills. In this review the full outline of the Candidiasis and the types and medication are put forth to be aware on the diseases caused by Candidiasis. According to FDA approval, the Ketoconazole is the first-line drug used for the treatment of the different types of Candidiasis.

**Keywords:** Candidiasis, Candida species, oesophageal or vaginal infections

### INTRODUCTION

The following are the two types of Candidiasis that are spreading in the current disease conditions.

#### I) MUCOSAL CANDIDIASIS

Opportunistic pathogens of the genus Candida is named as Mucosal candidiasis. It can be discussed as in two name mucosal and disseminated candidiasis <sup>[1]</sup>. According to oral, oesophageal or vaginal infections, is common in HIV/AIDS Mucosal candidiasis which varies from 7-93% infection <sup>[2]</sup>. The disseminated candidiasis named as a remarkably uncommon in AIDS. due to relatively adequate neutrophil function in most HIV-infected individuals.

**RISK FACTORS:** Neutropaenia, Parenteral nutrition, Abdominal surgery, Broad spectrum antibiotics, Cancer and corticosteroid use <sup>[3,4]</sup>

The following are the types of candidiasis that are related to the mucosal candidiasis:

#### Oropharyngeal Candidiasis:

The fungal infection of Candida species of mycosisca uses the oral candidiasis. In the presence of Candida albicans were the half the populations are caused by this candidiasis <sup>[5]</sup>.

#### Pseudomembranous Candidiasis:

It is also a class of oral candidiasis referred as trush. Around 35% of candidiasis are come across these category. Sometimes there will be an occurrence of bleeding beneath the mucosa as named as "curdled milk", the location of pseudomembranous candidiasis occurs on the tongue, buccal mucosae or palate <sup>[6]</sup>.

The following are the cases that come under pseudo membranous Candidiasis:

<b>Vaginal candidiasis</b>	Vaginal candidiasis is an infection of the vagina involving overgrowth of a
----------------------------	---

**How to cite this article:** V Sravanthi, VK Mayure, K Donthineni, CP Meher, GJ Finny; A Review on Candidiasis: Types and Medications; PharmaTutor; 2014; 2(9); 36-45

	yeast, or fungus, known as Candida. Over one million women are suffering with this type of candidiasis
<b>Oral candidiasis</b>	Oral candidiasis known as thrush, causes white, curd-like patches in the mouth or throat
<b>Deep organ candidiasis</b>	Candidiasis is a serious systemic infection that can affect the esophagus, heart, blood, liver, spleen, kidneys, eyes, and skin.

### **Erythematous Candidiasis:**

The type of candidiasis which appears as a red, raw-looking lesion is assayed as Erythematous (atrophic) candidiasis. Sub-types of Erythematous candidiasis are denture-related stomatitis, angular stomatitis, median rhomboid glossitis, and antibiotic-induced stomatitis<sup>[7]</sup>. Two types of candidiasis can be studied as: The candidiasis occurred in the dorsum of the tongue in persons taking long term corticosteroids or antibiotics is called as Acute erythematous candidiasis. This is usually termed "antibiotic sore mouth", "antibiotic sore tongue",<sup>[8]</sup> or "antibiotic induced stomatitis" because it is commonly painful as well as red. Chronic erythematous candidiasis is more usually associated with denture wearing (see denture-related stomatitis).

### **Hyperplastic Candidiasis:**

According to candidiasis, it is formation of white patch on<sup>[9]</sup> the commissures of the oral mucosa were behaved as variant of oral candidosis. The major etiologic agent of the disease is the oral fungal pathogen Candida predominantly belonging to Candida albicans, although other systemic co-factors, such as vitamin deficiency and generalized immune suppression. Lesions are the major formation in this type of candidiasis, if untreated it demonstrate dysplasia and develop into carcinomas, all this conditions are occurred in the Chronic hyperplastic candidosis/candidiasis. According to cernea et al, many oral leukoplakias are associated with Candida infections<sup>[10]</sup>. chronic mucocutaneous candidal lesions, encountered in patients with endocrine and immune defects, and affecting the skin and other mucosae, were

also described by some as chronic hyperplastic candidosis. The Group I lesions consist of the classic triad—pseudomembranous, erythematous, and hyperplastic variants<sup>[11]</sup>

### **Denture Related Stomatitis:**

Denture sore mouth/ chronic atrophic candidiasis/ denture-associated erythematous stomatitis is a common condition where mild inflammation and redness of the oral mucous membrane occurs beneath a denture. common form of oral candidiasis (a yeast infection of the mouth). It is more common in elderly people. The following are the types of Denture related stomatitis<sup>[12-15]</sup>:

- Type 1- Localized inflammation or pinpoint hyperemia.
- Type 2- More diffuse erythema (redness) involving part or all of the mucosa which is covered by the denture.
- Type 3- Inflammatory nodular/ papillary hyperplasia usually on the central hard palate and the alveolar ridge.

### **Angular Stomatitis:**

Inflammation of the corners of the lips is termed angular stomatitis or angular cheilitis.

- Children = repeated lip-licking.
- Adults = iron deficiency anemia, or vitamin B deficiencies
- Areas: jaws

According to this type of candidiasis, the skin folds around the angle of the mouth which are kept moist by saliva, which in turn favours infection; mostly by Candida albicans or similar species<sup>[16]</sup>.

*Medications:* nystatin, etc;

**Median Rhomboid Glossitis:**

Central papillary atrophy is the other name of Median rhomboid glossitis here condition characterized by an area of redness and loss of lingual papillae.

**Area:** dorsum of the tongue, circumvallate papillae<sup>[17-19]</sup>

**Candidal Vulvovaginitis(CV):**

It is the another type of candidiasis caused by candida albicans which causes infection to the vaginal mucosa membranes. Disease can be identified by vaginal itching or pain, burning with urination etc., it is also known as Vaginal thrush. The main reason to cause Candidal vulvovaginitis was hormonal imbalance. clotrimazole and fluconazole are used in the severe treatments<sup>[20-23]</sup>.

**75%**= Affected by CV

**5%** = Recurring episodes

*Candidal Balanitis:* Inflammation in the Glans refer to the Candidial Balanitis,

**RISK FACTORS:**

- Uncircumcised penis
- Antibiotic use
- Corticosteroid use
- Immunocompromised
- Poorly controlled diabetes

**DRUGS:** Clotrimazole, Miconazole, Anticoagulants<sup>[24-26]</sup>.

**Esophageal Candidiasis (Candid esophagitis):**

It is an esophagus inflammation, caused by immune compromised states, also called as monilial esophagitis.<sup>[27,28]</sup>

**DRUGS:** nystatin, itraconazole, caspofungin, amphotericin etc...,

**Candidal Intertrigo:**

Inflammation between intertriginous folds of adjacent skin is known as Candidal intertrigo. Intertrigo is also a known symptom of vitamin B6 deficiency<sup>[29]</sup>.

**DRUGS:** fluconazole, griseofulvin, and nystatin.

**Candidal Paronychia:**

Infection of nails and skin are known as candidal paronychia.

Sudden infection = Acute paronychia

Gradual infection = Chronic paronychia<sup>[30-32]</sup>

**DRUGS:** clindamycin or cephalixin

**Perianal Candidiasis:**

It is the another type of skin infection present as pruritus anicaused by Candida albicansand named as Perianal candidiasis.<sup>[33]</sup>

**Chronic Mucocutaneous Candidiasis:**

An immune disorder of T cellsis Chronic mucocutaneous candidiasis. It is caused by also other type of infection called human papilloma virus<sup>[34]</sup>.

**Congenital Cutaneous Candidiasis:** Also known as Beck-Ibrahim disease, occurs in newborn babies caused by premature rupture of membranes<sup>[35]</sup>

**Erosio Interdigitalis Blastomycetica:** Infection extends on the sides of fingers<sup>[36]</sup>.

**Onychomycosis :** Nail infection, "tinea unguium. This condition may affect toenails or fingernails, 10% of the adult population are suffered with Onychomycosis<sup>[37]</sup>

Distal subungual onychomycosis = Tinea unguium

White superficial onychomycosis = 10 percent of onychomycosis

Proximal subungual onychomycosis = Tinea unguium

Candidal onychomycosis = Damage of the nail<sup>[38,39]</sup>

**Invasive Candidiasis:** Invasive candidiasis is a fungal infection that can occur when Candida yeasts enter the bloodstream.

## II) DISSEMINATED CANDIDIASIS

### Antibiotic Candidiasis (iatrogenic candidiasis):

It is a Candidal infection caused by antibiotic use. Like overuse of broad-spectrum antibiotics, which are used for control of body pains.<sup>[40,41]</sup>

### Genitourinary Tract Candidiasis:

It is common fungal infections which lead to life-threatening invasive to non-life-threatening mucocutaneous diseases. Species involved are *Candida* spp., *Candida albicans*<sup>[42]</sup>,

Nongenitourinary candidiasis = Oropharyngeal manifestations

Genitourinary candidiasis = Vulvovaginal candidiasis<sup>[43]</sup>

### Renal Candidiasis:

Upper urinary tract that involves the renal pelvis and medulla related to Primary renal candidiasis. Species involved was *Candida* pyelonephritis, untreated disease may gradually progress to fungus ball (mycetoma) or abscess formation<sup>[44,45]</sup>.

### Candidemia:

*Candida albicans* and *Candida parapsilosis* are the two most frequent causes of candidemia in pediatric patients.<sup>[46]</sup>

**DRUGS:** fluconazole, an echinocandin, amphotericin B

### Hepatosplenic Candidiasis:

It is also called as Chronic disseminated candidiasis. It is occurred in patients with hematologic malignancies.<sup>[47]</sup>

### Candidal Onychomycosis:

Onychomycosis is usually caused by a dermatophyte, infections due to *Candida* species,

**DRUGS:** griseofulvin, terbinafine or itraconazole<sup>[48]</sup>,

### Candidal Skin Infections and Paronychia:

Non hematogenous primary skin infections

typically occur as intertrigo in skin folds, especially in obese and diabetic patients.

**DRUGS:** Azoles and polyenes, clotrimazole, miconazole, and nystatin<sup>[48]</sup>,

### Mammary Candidiasis:

Nipple or breast pain in nursing mothers has been linked to the presence of *C. albicans*,

**DRUGS:** nystatin and oral fluconazole<sup>[48]</sup>

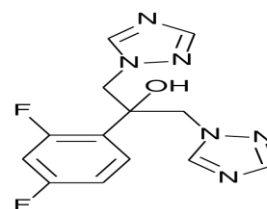
### Respiratory Tract Candidiasis:

Respiratory tract of a critically ill patient receiving mechanical ventilation (MV) usually indicates colonization rather than infection of the respiratory tract Candidiasis. Thus, *Candida* colonization of the respiratory tract may predispose to bacterial ventilator-associated pneumonia (VAP).<sup>[49]</sup>

### MEDICATIONS:

#### FLUCONAZOLE: Diflucan

Fluconazole inhibits the fungal cytochrome P450 enzyme 14 $\alpha$ -demethylase. Mammalian demethylase activity is much less sensitive to fluconazole than fungal demethylase. This inhibition prevents the conversion of lanosterol to ergosterol<sup>[50]</sup>, **Side effects are:** oliguria, hypokalaemia, paraesthesia, seizures, alopecia, Stevens–Johnson syndrome, thrombocytopenia<sup>[51]</sup>, etc;

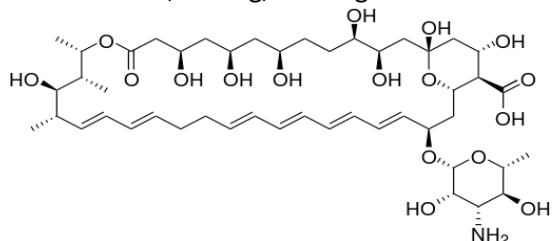


2-(2,4-Difluorophenyl)-1,3-bis(1H-1,2,4-triazol-1-yl)propan-2-ol

#### NYSTATIN: Nyamyc

Nystatin binds to fungal cell membrane. When present in sufficient concentrations, it forms pores in the membrane that lead to K<sup>+</sup> leakage, acidification, and death of the fungus.<sup>[52]</sup> **side**

**effects are:** Hypersensitivity Reactions, including Stevens-Johnson syndrome in some cases [53] Rash, itching, burning

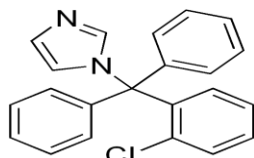


(1S,3R,4R,7R,11R,16R,17R,18S,19E,21E,25E,27E,29E,31E,33R,35S,36R,37S,-)33-[(3-amino-3,6-dideoxy-beta-L-mannopyranosyl)oxy]-1,3,4,7,9,11,17,31-octahydroxy-15,16,18-trimethyl-13-oxo-14,39-dioxabicyclo[3.3.1]nonatriaconta-19,21,25,27,29,31-hexane-36-carboxylic acid.

#### CLOTRIMAZOLE: Desenex:

Clotrimazole works to kill individual Candida or fungal cells by altering the permeability of the fungal cell wall. It binds to phospholipids in the cell membrane and inhibits the biosynthesis of ergosterol and other sterols required for cell membrane production. This leads to the cell's death [54]

**side effects are:** itching, nausea, and vomiting. polyuria, vulvar itching, soreness, edema, or discharge [55]

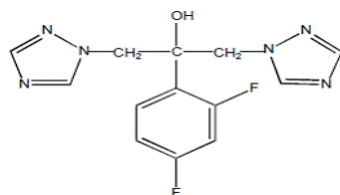


1-[(2-Chlorophenyl)(diphenyl)methyl]-1H-imidazole

#### DIFLUCAN:

Mechanism explains same as Flucanazole,

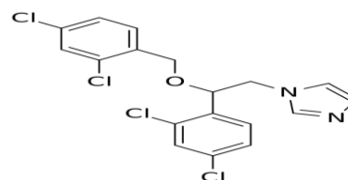
**side effects are:** Nausea, vomiting, diarrhea, stomach upset/pain, headache, dizziness, or hair loss. [56]



2,4-difluoro- $\alpha,\alpha^1$ -bis(1H-1,2,4-triazol-1-ylmethyl)

#### MICONAZOLE: Monistat

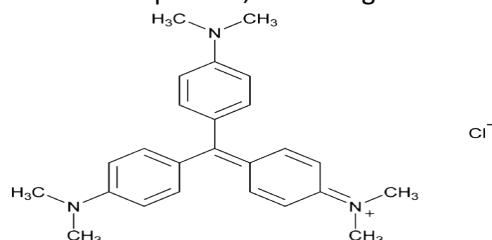
Inhibiting the synthesis of ergosterol, a critical component of fungal cell membranes, **side effects are:** hypercholesterolemia. Rash, itching, burning. [57]



RS)-1-(2-(2,4-Dichlorobenzoyloxy)-2-(2,4-dichlorophenyl)ethyl)-1H-imidazole

#### GENTIAN:

It is applied to the skin for treating wounds and cancer. It is used for digestion problems such as loss of appetite, fullness, intestinal gas, diarrhea, gastritis, heartburn, and vomiting. It is also used for fever, hysteria, and high blood pressure. Some people use gentian to prevent muscle spasms, treat parasitic worms, start menstrual periods, and as a germ killer. [58]

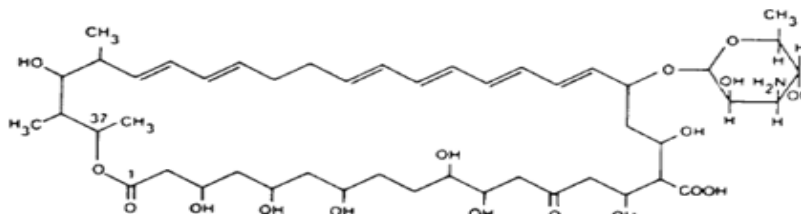


4-{bis[4-(dimethylamino)phenyl]methylidene}-N,N-dimethylcyclohexa-2,5-dien-1-iminium

#### NYSTATIN-TRIAMCINOLONE:

It contains antifungal and a corticosteroid medicine, used for fungus infection like Candida (Monilia),

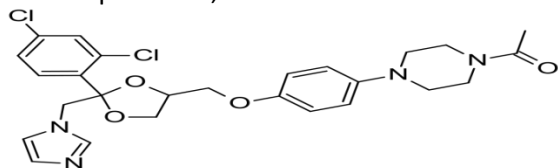
**side effects are :** unusual/extreme tiredness, weight loss, headache, swelling ankles/feet, increased thirst/urination, vision problems. [59]



### Ketoconazole:

It is a synthetic, imidazole antifungal medication used primarily to treat fungal infections. used to treat tinea; cutaneous candidiasis, including candidal paronychia; and pityriasis versicolor) and shampoos (used primarily to treat dandruff—seborrheic dermatitis of the scalp) [60]

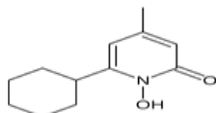
**some of the side effects are:** liver damage, adrenal problems,



1-[4-(4-[[[(2R,4S)-2-(2,4-Dichlorophenyl)-2-(1H-imidazol-1-ylmethyl)-1,3-dioxolan-4-yl]methoxy}phenyl)piperazin-1-yl]ethan-1-one

### Ciclopirox:

It is a synthetic antifungal agent for topical dermatologic treatment of superficial mycoses. It is most useful against Tinea versicolor.<sup>[61]</sup> loss of function of certain catalase and peroxidase enzymes has been implicated as the mechanism of action, as well as various other components of cellular metabolism.

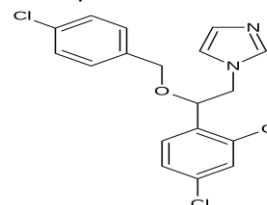


6-cyclohexyl-1-hydroxy-4-methylpyridin-2(1H)-one

### Econazole:

It is an antifungal medication of the imidazole class. Used to treat skin infections such as athlete's foot, tinea, pityriasis versicolor, ringworm, and jock itch. The most common

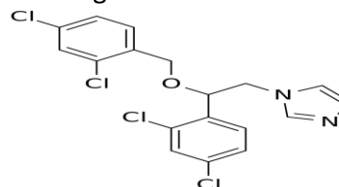
symptoms were burning, itching, erythema, and one outbreak of a pruritic rash.<sup>[62]</sup>



(RS)-1-[2-[(4-Chlorophenyl)methoxy]-2-(2,4-dichlorophenyl)ethyl]-1H-imidazole

### Miconazole nitrate:

Miconazole is used to treat skin infections such as athlete's foot, jock itch, ringworm, and other fungal skin infections (candidiasis). This medication is also used to treat a skin condition known as pityriasis (tinea versicolor), a fungal infection that causes a lightening or darkening of the skin of the neck, chest, arms, or legs. symptoms of a serious allergic reaction, including: rash, itching/swelling (especially of the face/tongue/throat), severe dizziness, trouble breathing.<sup>[63]</sup>

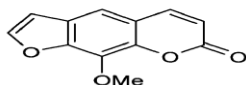


(RS)-1-(2-(2,4-Dichlorobenzoyloxy)-2-(2,4-dichlorophenyl)ethyl)-1H-imidazole

### Fungoid:

Fungoides is also known as Alibert-Bazin syndrome<sup>[64]</sup> or granuloma fungoides, is the most common form of Cutaneous T-cell lymphoma. Treatment options include sunlight

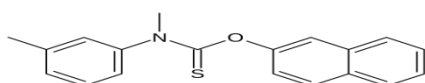
exposure, ultraviolet light, topical steroids, chemotherapy, and radiation.



8-methoxypsoralen

#### Tolnaftate:

It is a synthetic thiocarbamate used as an anti-fungal agent. Tolnaftate is used to treat fungal conditions such as jock itch, athlete's foot and ringworm.



O-2-naphthyl methyl(3-methylphenyl)thiocarbamate

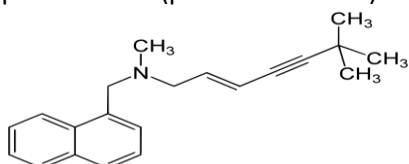
#### Triple Dye:

It is an antiseptic consisting of the aniline dyes gentian violet, brilliant green, and acriflavine that was originally used in the treatment of burns and later as a general bactericide

#### Terbinafine:

Terbinafine hydrochloride is a synthetic allylamine antifungal. It is highly hydrophobic in nature and tends to accumulate in skin, nails, and fatty tissues.<sup>[66]</sup>

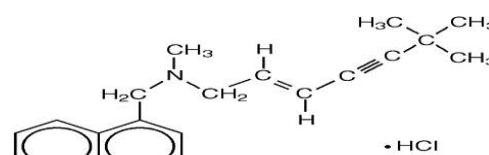
**side effects are:** Diarrhea, constipation, nausea, sickness, fullness, abdominal pain, indigestion, dyspepsia, gastritis, cholestasis, flatulence, altered stool colour, abdominal muscular pain. Headaches, dizziness, vertigo, light-headedness, decreased concentration levels, paraesthesia (pins and needles)



[(2E)-6,6-dimethylhept-2-en-4-yn-1-yl](methyl)(naphthalen-1-ylmethyl)amine

#### Lamisil AT:

These drugs Relieves itching, burning, cracking, and scaling associated with jock itch, athlete's foot, ringworm, and other fungal infections of the skin. Lamisil AT cream is topical antifungal agent. It works by killing sensitive fungi. **Severe allergic reactions** (rash; hives; itching; difficulty breathing; tightness in the chest; swelling of the mouth, face, lips, or tongue); new or worsening skin irritation.



(2E)-N,6,6-Trimethyl-N-(1-naphthylmethyl)-2-hepten-4-yn-1-amine hydrochloride (1:1)

#### Miconazole-lanolin:

Drugs are used to treat Ringworm of Groin Area, Athlete's Foot, Ringworm of the Body, Fungal Infection of the Skin with Yellow Patches, Skin Infection due to a Candida Yeast.

**Side effects are:** Redness of Skin, Small Skin Blister, Rash, Skin Irritation, Reaction due to an Allergy, Numbness and Tingling.

#### CONCLUSION

Thrush is the other name of Candidiasis / Candidosis / Moniliasis / Oidiomycosis, as we know that the Candidiasis is the fungal infection caused by C.albicans. Therefore, there are different type of Candidiasis which are harmful for the humans. Several treatments to be taken on the Candidiasis, amongst the all anti-candidiasis agents, ketaconazole is the first-line drugs. As we discussed in the abstract, I in this review demonstrated the key study of the current disease called as a new era disease as Candidiasis can be elaborated with their types of diseases and treatment by suitable agents.

## ↓ REFERENCES

1. Mocroft A, Oancea C, van Lunzen J, et al. Decline in esophageal candidiasis and use of antimycotics in European patients with HIV. *Am J Gastroenterol* 2005; 100: 1446-54.
2. Chan KCW, Wong KH, Lee SS. HIV Infection in Women: the Hong Kong Experience to date. First Annual Scientific Meeting, Hong Kong Society for Infectious Disease. Hong Kong, 1997.
3. Manfredi R, Calza L, Chiodo F. Dual *Candida albicans* and *Cryptococcus neoformans* fungaemia in an AIDS presenter: a unique disease association in the highly active antiretroviral therapy (HAART) era. *J Med Microbiol* 2002; 51:1135-7.
4. Garbino J, Kolarova L, Lew D, Hirschel B, Rohner P. Fungemia in HIV-infected patients: a 12-year study in a tertiary care hospital. *AIDS Patient Care STDS* 2001; 15: 407-10.
5. Kerawala C, Newlands C (editors). *Oral and maxillofacial surgery*. Oxford: Oxford University Press. 2010; pp. 446, 447.
6. Treister NS, Bruch JM. *Clinical oral medicine and pathology*. New York: Humana Press. 2010; pp. 19, 21, 92, 93.
7. Rhodus, NL. "Treatment of oral candidiasis." *Northwest dentistry* Mar–Apr 2012, 91 (2): 32–3.
8. Soames JV, Southam JC, JV. *Oral pathology* (3rd ed) Oxford: Oxford Uni. Press. 1999; pp. 147, 193–200.
9. Cernea P, Crepy C, Kuffer R, Mascaro JM, Badillet G, Marie JL. Aspects peu connus de candidosis buccales. Les Candidases à foyers multiples de la cavité buccale. *Rev Stomatol (Paris)* 1965; 66:103–138.
10. Cawson RA, Lehner T. Chronic hyperplastic candidosis-candidal leukoplakia. *Br J Dermatol N* 1968; 80:9–16.
11. Holmstrup P, Besserman M. Clinical, therapeutic and pathogenic aspects of chronic oral multifocal candidiasis. *Oral Surg Oral Med Oral Pathol*, 1983; 56:388–395.
12. Bouquot, Brad W. Neville, Douglas D. Damm, Carl M. Allen, Jerry E. *Oral & maxillofacial pathology* (2nd ed.). Philadelphia: W.B. Saunders. 2002; pp. 192–194.
13. Tyldesley, Anne Field, Lesley Longman in collaboration with William R. Tyldesley's *Oral medicine* (5th ed.). Oxford: Oxford University Press. 2003; pp. 35–40.
14. Manfredi, M; Polonelli, L; Aguirre-Urizar, J; Carrozzo, M; McCullough, "Urban legends series: oral candidosis." *Oral diseases*. Aug 14, 2012.
15. Scully, Crispian. *Oral and maxillofacial medicine: the basis of diagnosis and treatment* (2nd ed.). Edinburgh: Churchill Livingstone. 2008; pp. 201–203.
16. Brocklehurst P; Tickle, M; Glenny, AM; Lewis, MA; Pemberton, MN; Taylor, J; Walsh, T; Riley, P; Yates, JM. "Systemic interventions for recurrent aphthous stomatitis (mouth ulcers)." In Brocklehurst, Paul. *The Cochrane database of systematic reviews* 9; Sep 12, 2012
17. Rapini, Ronald P; Bologna, Jean L; Jorizzo, Joseph L. *Dermatology: 2-Volume Set*. St. Louis: Mosby, 2009.
18. Scully, Crispian. *Oral and maxillofacial medicine: the basis of diagnosis and treatment* (2nd ed.). Edinburgh: Churchill Livingstone. 2008; pp. 196–198.
19. James, William D.; Berger, Timothy G.; et al. *Andrews' Diseases of the Skin: Clinical Dermatology*. Saunders Elsevier. 2006.
20. James, William D.; Berger, Timothy G.; et al. *Andrews' Diseases of the Skin: clinical Dermatology*. Saunders Elsevier. 2006; p. 309.
21. Sobel, JD. "Vulvovaginal candidosis." *Lancet*, 9 June 2007; 369 (9577): 1961–71.
22. Workowski KA, Berman SM. "Sexually transmitted diseases treatment guidelines, 2006". *MMWR Recomm Rep* 55 , August 2006 ;(RR-11): 1–94.
23. Ilkit, M; Guzel, AB. "The epidemiology, pathogenesis, and diagnosis of vulvovaginal candidosis: a



- mycological perspective". *Critical reviews in microbiology*, August 2011; 37 (3): 250–61.
24. Habib, T. *Clinical Dermatology: A color guide to diagnosis and therapy*. 3rd edition. Mosby, 1996.
  25. Holmes, K., Sparling, P., Stamm, W., Piot, P., Wasserheit, J., Corey, L., Cohen, M., Watts, H. *Sexually transmitted disease (4th ed)*. Toronto, ON: McGraw Hill Medical. 2008.
  26. McMillan, A., Young, H., Ogilvie, M., Scott, G. *Clinical Practice in Sexually Transmissible Infections*. Saunders: London. 2002.
  27. Mimidis, K; Papadopoulos, V; Margaritis V; Thomopoulos, K; Gatopoulou, A; Nikolopoulou, V; Kartalis, G. "Predisposing factors and clinical symptoms in HIV-negative patients with *Candida* oesophagitis: are they always present?". *International journal of clinical practice*, Feb 2005; 59 (2): 210–3.
  28. Hamza OJM, Matee MIN, Brüggemann RJM, et al. "Single-dose fluconazole versus standard 2-week therapy for oropharyngeal candidiasis in HIV-infected patients: A randomized, double-blind, double-dummy trial". *Clin Infect Dis*, 2008; 47 (10): 1270–1276.
  29. James, William D.; Berger, Timothy G. et al; *Andrews' Diseases of the Skin: clinical Dermatology*. Saunders Elsevier. 2006.
  30. Rigopoulos D, Larios G, Gregoriou S, Alevizos A. "Acute and chronic paronychia". *Am Fam Physician*, Feb 2008; 77 (3): 339–46.
  31. Rockwell PG. "Acute and chronic paronychia". *Am Fam Physician*, Mar 2001; 63 (6): 1113–6.
  32. Ritting, AW; O'Malley, MP; Rodner, CM. "Acute paronychia.". *The Journal of hand surgery*, May 2012; 37 (5): 1068–70;
  33. James, William D.; Berger, Timothy G.; et al. *Andrews' Diseases of the Skin: clinical Dermatology*. Saunders Elsevier. 2006.
  34. Rapini, Ronald P.; Bologna, Jean L.; Jorizzo, Joseph L. *Dermatology: 2-Volume Set*. St. Louis: Mosby. 2007.
  35. Strous, Rael D.; Edelman, Morris C. "Eponyms and the Nazi Era: Time to Remember and Time for Change". *Israel Medical Association Journal*, 2007; 9: 207–214.
  36. James, William D.; Berger, Timothy G.; et al. *Andrews' Diseases of the Skin: clinical Dermatology*. Saunders Elsevier. 2006.
  37. Rapini, Ronald P.; Bologna, Jean L.; Jorizzo, Joseph L. *Dermatology: 2-Volume Set*. St. Louis: Mosby. 2007; p. 1135.
  38. Westerberg D, Voyack MJ. "Onychomycosis: Current Trends in Diagnosis and Management". *Am Fam Physician (Review)*, Dec 2013; 88 (11): 762–70.
  39. James, William D.; Berger, Timothy G. *Andrews' Diseases of the Skin: clinical Dermatology*. Saunders Elsevier.
  40. James, William D.; Berger, Timothy G.; et al. *Andrews' Diseases of the Skin: clinical Dermatology*. Saunders Elsevier. 2006.
  41. Schiefer HG. "Mycoses of the urogenital tract". *Mycoses* 40 Suppl 2: 33–6. 1997.
  42. de Repentigny, L., D. Lewandowski, and P. Jolicoeur. Immunopathogenesis of oropharyngeal candidiasis in human immunodeficiency virus infection. *Clin. Microbiol.* 2004; Rev.17:729-759.
  43. Richards MJ, JR. Edwards, D. H. Culver, and R. P. Gaynes. Nosocomial infections in combined medical-surgical intensive care units in the United States. *Infect. Control Hosp. Epidemiol.* 2000; 21:510-515.
  44. Lundstrom T, Sobel J. Nosocomial candiduria: a review. *Clin Infect Dis* 2001; 32:1602–1607.
  45. Richards MJ, Edwards JR, Culver DH, Gaynes RP. Nosocomial infections in medical intensive care units in the United States. National Nosocomial Infections Surveillance System. *Crit Care Med* 1999; 27:887–892.
  46. Zaoutis T, Candidemia in children, *Curr Med Res Opin.* pub med. 2010 Jul; 26(7):1761-8

47. Thaler M, Pastakia B, Shawker TH, et al. Hepatic candidiasis in cancer patients: the evolving picture of the syndrome. *Ann Intern Med* 1988; 108:88.
48. Elewski BE. Large-scale epidemiological study of the causal agents of onychomycosis: mycological findings from the Multicenter Onychomycosis Study of Terbinafin. *Arch Dermatol* 1997; 133:1317-8.
49. Azoulay E1, Timsit JF, Tafflet M, de Lassence A, Darmon M, Zahar JR, Adrie C, Garrouste-Orgeas M, Cohen Y, Mourvillier B, Schlemmer B; Outcomerea Study Group. Candida colonization of the respiratory tract and subsequent pseudomonas ventilator-associated pneumonia, *PUBMED, Chest*. 2006 Jan; 129(1):110-7.
50. Pfizer Australia Pty Ltd. Diflucan (Australian Approved Product Information). West Ryde (NSW): Pfizer Australia; 2004
51. Rossi S, editor. *Australian Medicines Handbook* 2006. Adelaide: Australian Medicines Handbook; 2006.
52. Hammond, S.M. "Biological activity of polyene antibiotics." *Progress in medicinal chemistry*. 1977; 14 (105-179).
53. "FDA approved package insert".
54. "Clotrimazole (Oral)". *Lexicomp Online*. Retrieved 17 April 2014.
55. "Clotrimazole: MedlinePlus Drug Information". *The American Society of Health-System Pharmacists, Inc*. Retrieved 17 April 2014.
56. Clinical and Laboratory Standards Institute (CLSI). *Reference Method for Broth Dilution Antifungal Susceptibility Testing of Yeasts; Approved Standard-Third Edition*. CLSI Document M27-A3, Clinical and Laboratory Standards Institute, 940 West Valley Road, Suite 1400, Wayne, PA, 19087-1898 USA, 2008
57. "WHO Model List of Essential Medicines". *World Health Organization*. October 2013. Retrieved 22 April 2014.
58. Vogl S, Picker P, Mihaly-Bison J, Fakhrudin N, Atanasov AG, Heiss EH, Wawrosch C, Reznicek G, Dirsch VM, Saukel J, Kopp B. Ethnopharmacological in vitro studies on Austria's folk medicine - An unexplored lore in vitro anti-inflammatory activities of 71 Austrian traditional herbal drugs. *J Ethnopharmacol*. 2013 Jun 13.
59. [webmd.com/drugs/drug-2768-Nystatin Triamcinolone](http://webmd.com/drugs/drug-2768-Nystatin-Triamcinolone)
60. Rossi, S, ed. *Australian Medicines Handbook* (2013 ed.). Adelaide: The Australian Medicines Handbook Unit Trust. 2013.
61. Niewerth M, Kunze D, Seibold M, Schaller M, Korting HC, Hube B. "Ciclopirox Olamine Treatment Affects the Expression Pattern of Candida albicans Genes Encoding Virulence Factors, Iron Metabolism Proteins, and Drug Resistance Factors". *Antimicrobial Agents and Chemotherapy*, June 2003; 47 (6): 1805–17.
62. Thienpont, D; Van Cutsem, J; Van Nueten, JM; Niemegeers, CJ; Marsboom, R. "Biological and toxicological properties of econazole, a broad-spectrum antimycotic". *Arzneimittel-Forschung*, 1975; 25 (2): 224–30.
63. Ju, Jiang; Tsuboi, Ryoji ; Kojima, Yuko ; Ogawa, Hideoki (2005). "Topical application of ketoconazole stimulates hair growth in C3H/HeN mice". *Journal of dermatology* 32: 243–247.
64. Rapini, Ronald P. *Bologna, Jean L.; Jorizzo, Joseph L. Dermatology: 2-Volume Set*. St. Louis: Mosby, 2007; p. 1867.
65. Noguchi, T.; Hashimoto, Y.; Miyazaki, K.; Kaji, A.; *J. Pharm. Soc. Japan* 1968, 88, 335
66. Callen JP, Hughes AP, Kulp-Shorten C "Subacute cutaneous lupus erythematosus induced or exacerbated by terbinafine: a report of 5 cases". *Arch Dermatol* Sep 2001; 137 (9): 1196–8.